

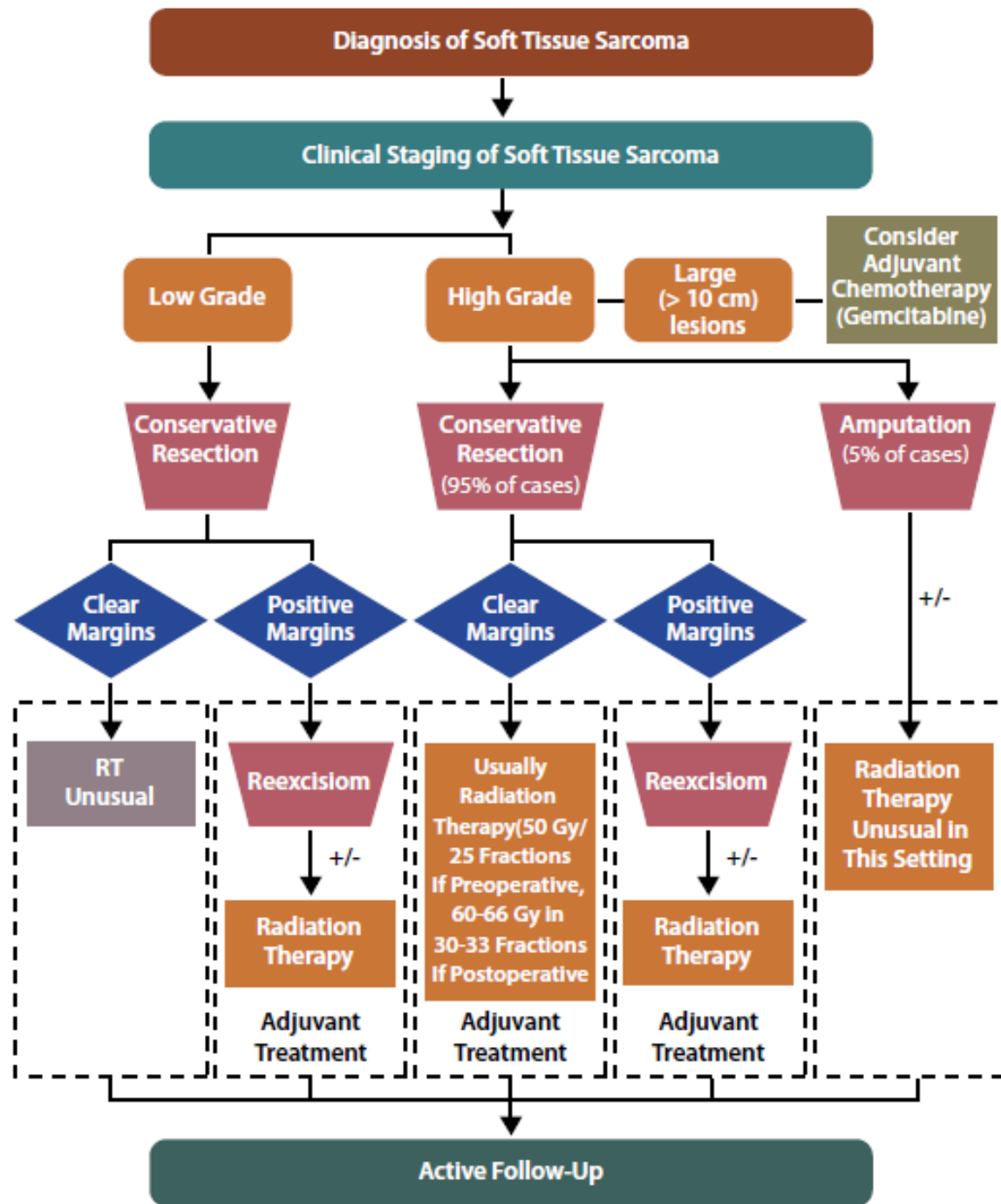
UC San Diego Health

Soft Tissue Extremity Sarcoma

Clinical Case conference



Treatment Techniques and Principles





ELSEVIER

Int. J. Radiation Oncology Biol. Phys., Vol. 81, No. 4, pp. e525–e528, 2011

Copyright © 2011 Elsevier Inc.

Printed in the USA. All rights reserved

0360-3016/\$ - see front matter

doi:10.1016/j.ijrobp.2011.04.038

CLINICAL INVESTIGATION

Sarcoma

**RTOG SARCOMA RADIATION ONCOLOGISTS REACH CONSENSUS ON GROSS
TUMOR VOLUME AND CLINICAL TARGET VOLUME ON COMPUTED
TOMOGRAPHIC IMAGES FOR PREOPERATIVE RADIOTHERAPY OF PRIMARY
SOFT TISSUE SARCOMA OF EXTREMITY IN RADIATION THERAPY ONCOLOGY
GROUP STUDIES**

DIAN WANG, M.D., PH.D.,* WALTER BOSCH, PH.D.,† DAVID ROBERGE, M.D.,‡
STEVEN E. FINKELSTEIN, M.D.,¶ IVY PETERSEN, M.D.,§ MICHAEL HADDOCK, M.D.,§
YEN-LIN E. CHEN, M.D.,** NAOYUKI G. SAITO, M.D., PH.D.,** DAVID G. KIRSCH, M.D., PH.D.,††
YING J. HITCHCOCK, M.D.,‡‡ AARON H. WOLFSON, M.D.,¶¶ AND THOMAS F. DELANEY, M.D.¶¶

*Medical College of Wisconsin, Milwaukee, WI; †Washington University, St. Louis, MO; ‡McGill University, Montreal, Quebec;
§Mayo Clinic, Rochester, MN; ¶Moffitt Cancer Center, Tampa, FL; §Massachusetts General Hospital, Boston, MA; **Roswell Park
Cancer Institute, Buffalo, NY; ††Duke University, Durham, NC; ‡‡University of Utah, Salt Lake City, UT; and ¶¶University of Miami
Miller School of Medicine, Miami, FL

RTOG Consensus Guidelines

- GTV is defined by T1 MRI with contrast (may include edema on T2 as well)
- CTV = GTV + 3cm longitudinally and 1.5cm radially
 - OK to trim when extending outside compartment or into skin/bone
- CTV -> PTV expansion is institution dependent
- **RTOG 0630

RADIATION THERAPY ONCOLOGY GROUP

RTOG 0630

**A Phase II Trial of Image Guided Preoperative Radiotherapy
for Primary Soft Tissue Sarcomas of the Extremity**

SCHEMA

	Preoperative IGRT (3D-CRT or IMRT)		Postoperative Radiotherapy Boost <u>For patients with positive margins</u>
		<u>All patients:</u>	
			<u>External beam RT</u>
R	<u>Cohort A (Closed 1/8/10)</u>		2 weeks post-surgery
E	Patients receiving neoadjuvant or adjuvant	Surgery	16 Gy in 8 daily fractions
G	chemotherapy or both = 50 Gy in 25 daily fractions	4-8 weeks	OR
I	OR	after	<u>Brachytherapy</u>
S	Patients receiving concurrent or interdigitated	completion of	5 days post-surgery
T	chemotherapy = 44 Gy in 22 daily fractions	preoperative	LDR = 16 Gy at ≤ 80 cGy per hour
E		RT (and chemo	OR
R	<u>Cohort B</u>	if given)	HDR = 3.4 Gy/fraction in 4 fractions
	Patients not receiving chemotherapy =		with at least 6 hours between fractions
	50 Gy in 25 daily fractions		OR
			<u>Intraoperative RT</u>
			10-12.5 Gy in a single fraction

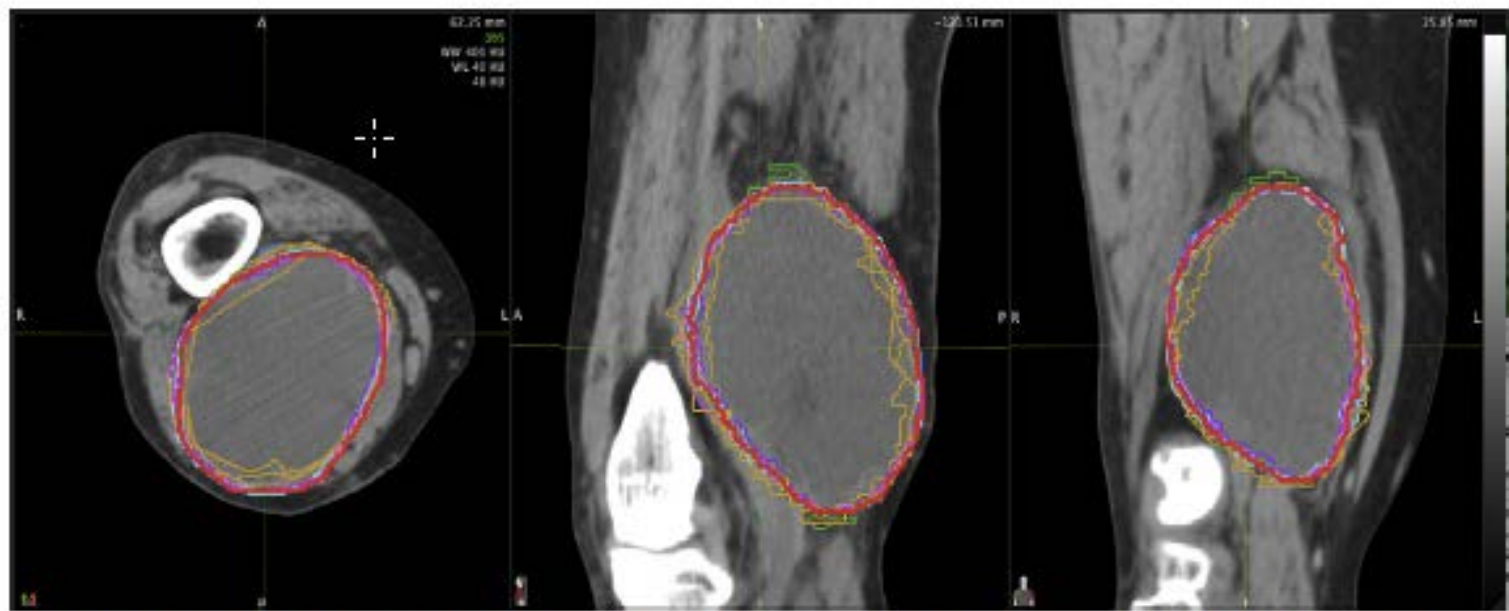

Fig. 1. Example of individual and consensus (red) contours of gross tumor volume on axial computed tomography for patient with large high-grade sarcoma of distal aspect of right thigh.

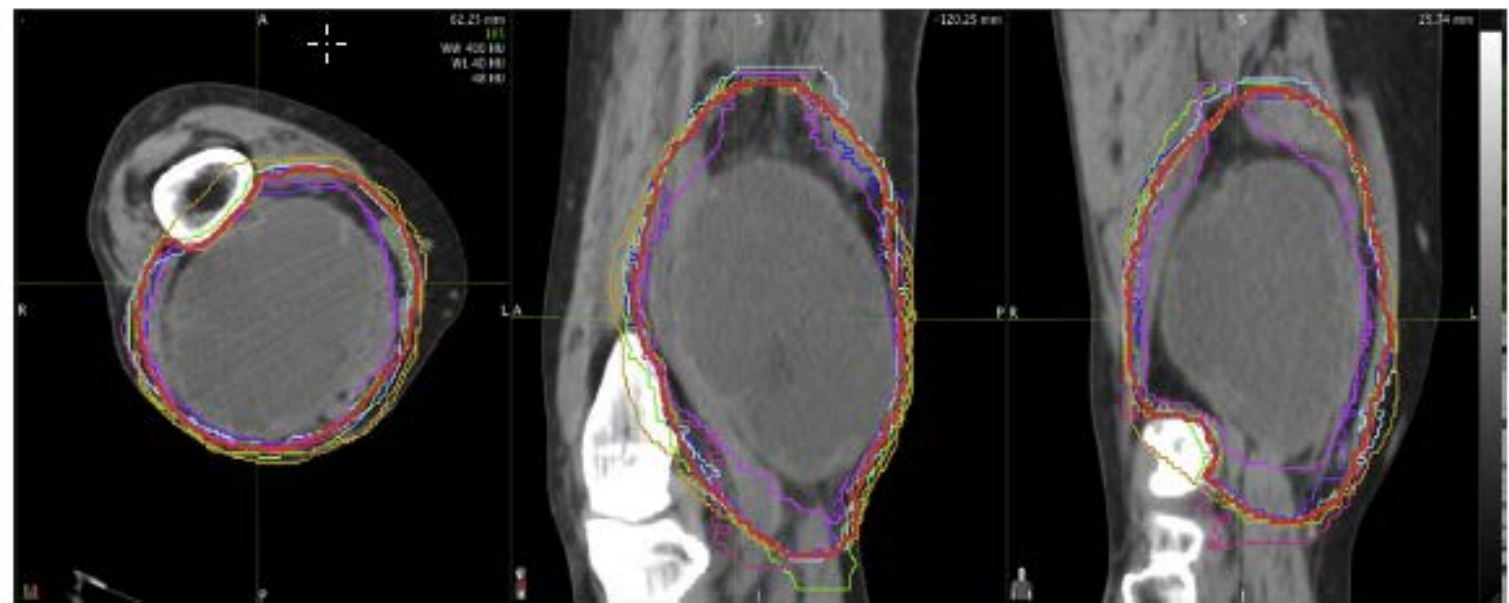


Fig. 2. Example of individual and consensus (red) contours of clinical target volume on axial computed tomography for patient with large high-grade sarcoma of distal aspect of right thigh.

6.4 Treatment Planning/Target Volumes

6.4.1 Target Definition

The definition of volumes will be in accordance with the ICRU Report #62: Prescribing, recording and Reporting Photon Beam Therapy (supplement to ICRU Report #50).

6.4.1.1 Gross Target Volume (GTV): Gross tumor defined by MRI T1 plus contrast images (MRI with contrast is required). Fusion of MRI and CT is recommended to delineate the GTV for radiotherapy planning, but this is optional.

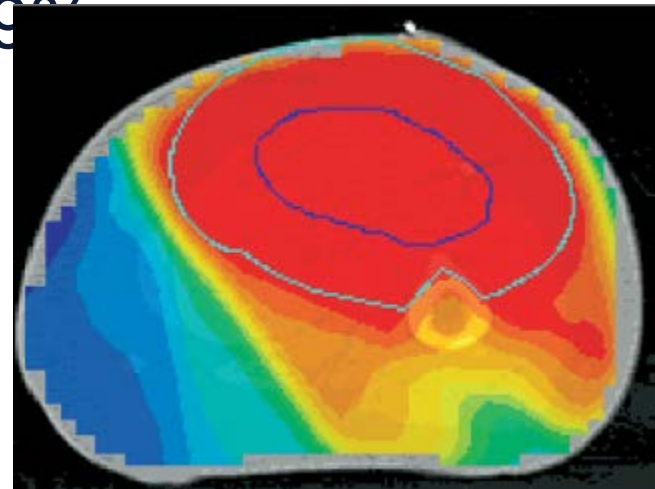
6.4.1.2 (4/20/09) Clinical Target Volume (CTV) for Intermediate-to-High Grade Tumors ≥ 8 cm: Include gross tumor and clinical microscopic margins. Typically CTV = GTV and suspicious edema (defined by MRI T2 images) plus 3 cm margins in the longitudinal (proximal and distal) directions. If this causes the field to extend beyond the compartment, the field can be shortened to include the end of a compartment. The radial margin from the lesion should be 1.5 cm including any portion of the tumor not confined by an intact fascial barrier or bone or skin surface.

6.4.1.3 (4/20/09) CTV For All Other Tumors: Include gross tumor and clinical microscopic margins. Typically CTV = GTV and suspicious edema (defined by MRI T2 images) plus 2 cm margins in the longitudinal (proximal and distal) directions. If this causes the field to extend beyond the compartment, the field can be shortened to include the end of compartment. The radial margin from the lesion should be 1 cm including any portion of the tumor not confined by an intact fascial barrier or bone or skin surface.

6.4.1.4 Planning Target Volume (PTV): Include CTV and error of setup and organ motion. Typically PTV includes CTV plus 5 mm.

IMRT

- Alektiar et al. – MSKCC – IJROBP 2007
- 31pts
- Pre-op RT was 50Gy (w/ 16Gy boost if +mgn), post-op RT was 63Gy
- 2yr LC was 95%
- Rate of grade 2+ Edema was 13%
and rate of grade 2+ fibrosis was 19%
- Wound complications in 23%
- Fracture developed in 6%



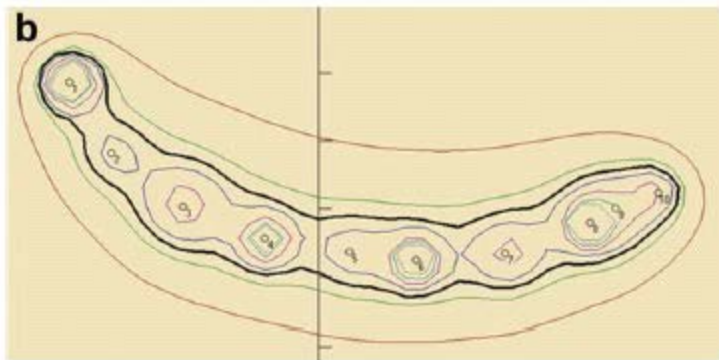
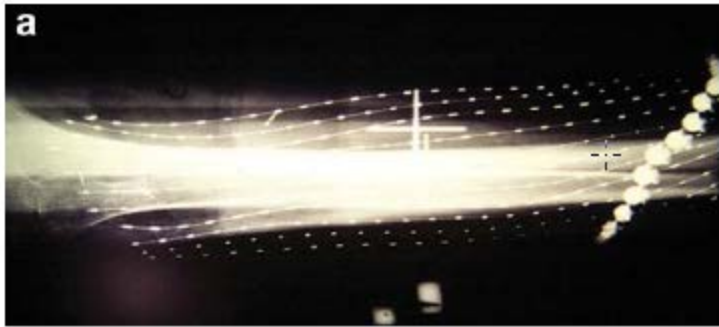
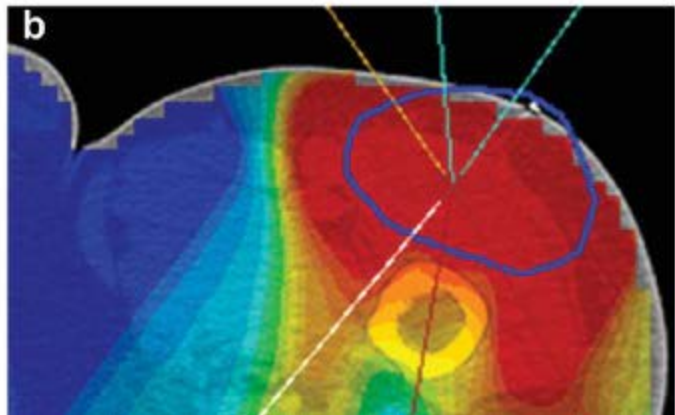
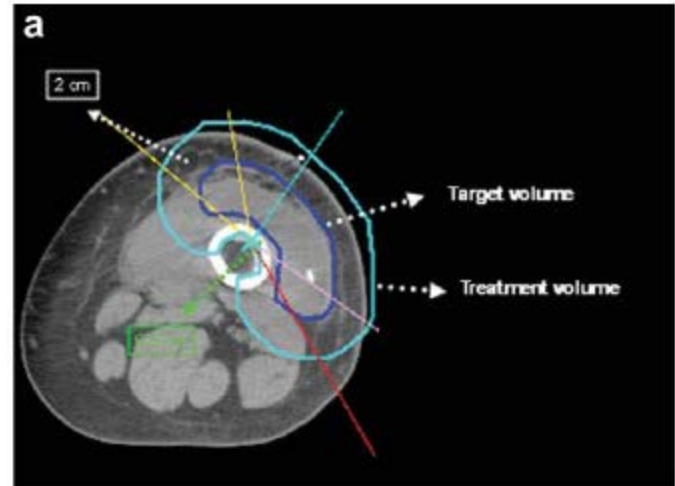


Figure 1. Brachytherapy. (a) Plain X-ray film demonstrating afterloading catheters. (b) Axial dose rate distribution. Solid line represents prescription isodose rate line.



- Additional References:

- Halperin, Perez & Brady “Principles and practice of Radiation Oncology” 5th ed.
- AJCC cancer staging handbook 7th ed.
- Hansen and Roach III “Handbook of evidence-based Radiation Oncology” 2nd ed.
- http://en.wikibooks.org/wiki/Radiation_Oncology
- Hall and Giaccia “Radiobiology for the radiologist” 6th ed.